



EFFECT OF ETHANOLIC LEAVE EXTRACT OF MIMOSA PUDICA L. ON DIABETIC WOUND HEALING ACTIVITY IN RATS

Santosh Kumar.R^{1*}, Rajkiran.K¹ and Sunil Kumar Patnaik¹

¹Pharmacology Division, Vignan Institute of Pharmaceutical Technology, Visakhapatnam, Andhra Pradesh, India

*Corresponding author E-mail: Email- sanrancol@gmail.com,

ARTICLE INFO

ABSTRACT

Key Words:

Mimosa pudica, Diabetes mellitus, Excision wound



Based Diabetes mellitus (DM) patients have greater susceptibility to serious infections leading to difficulty in healing of wounds. The herbal drugs are gaining more attention in the treatment of delayed wound healing during DM than synthetic drugs. The present study is designed to evaluate ethanolic leave extract of *Mimosa pudica* L. (EMP) on wound healing activity in Streptozotocin induced diabetic rats. Diabetes was induced in male albino wistar rats with Streptozotocin (55 mg/kg, i.p.). A 500 mm² of excision (biopsy) wound is made on the backside of the rat. Two different dose (2.5% & 5%) ointments are prepared in simple ointment base and the ointment is applied twice topically for 18 days. The fasting serum glucose level was estimated on initial as well as final day of experiment to confirm the disease state. The area of wound healed and % of wound closure are estimated on every 6 days interval. The EMP 2.5 % and EMP 5% have shown significant diabetic wound healing activity when compared to disease control group. The leaf of *Mimosa pudica* is traditionally used in the treatment of many disorders like swelling, fistula, sores, hemorrhoids and wound, might be due to its alkaloid, tannin, phenolic and flavonoid contain. In the present study the EMP treated groups has shown fast collagenation and scar formation when compared to disease control group.

INTRODUCTION:

Diabetes mellitus (DM) is a progressive metabolic disorder characterized by insulin insufficiency, insulin resistance or both. The type 2 DM (T2DM) is more prevalent and is associates with a number of manifestations like microvascular and macrovascular disorders, which may be the prime reason for the morbidity and mortality in the world population. It is estimated that the prevalence of DM in world population is more than 150 million¹. The T2DM patients have greater susceptibility to serious infections due to several factors, including lower chemotaxis and phagocytic activity by neutrophils. These patients are also more vulnerable to bacterial infections and subsequently cause delay in the healing of wounds which is a complex process that requires the interactions of different cells

and extracellular molecules. There is a raise in cost for the delivery of better health care in diabetes. The diabetic foot ulcer or wound is a common in the elderly in the latter stage of diabetic life period. The annual cost to manage these wounds exceeds 20 billion dollars with a loss of over two million work days. The diabetic foot ulcer in particular is more difficult to treat, costing between \$7,000 and \$10,000 per ulcer. Many of these ulcers may ultimately require amputation of a limb, where the cost may be as high as \$65,000 per person². Healing is a consequence of biological events that are complex and dynamic to promote the repair of damage after an injury³. Further, it has been well accepted that the herbal drugs are gaining more attention in the treatment of delayed diabetic

wound healing in comparison to synthetic drugs. It has been reported that several traditional medicines are used for the purpose of wound healing properties such as *Aloe vera*, *Calotropis procera*, *Portulaca oleracea*, *Acalypha langiana*, *Plagiochasma appendiculatu* & *Momordica charantia*. Therefore, there is still scope to develop a potent drug in the healing of diabetic wound. *Mimosa pudica* L. belongs to the genus *Mimosa* (Family: Fabaceae alt. Leguminosae) is popularly named as a sensitive and shy plant. In the ancient days Charaka and Susruta have mentioned various properties of *Mimosa pudica* in Ayurveda such as sophahara (reduces edema), yoniragahara (ameliorates vaginal disease), atisaraghna (anti-diarrhoeal), kustahara (anti dermatoses). Maharishi Charak has categorized it as sandhaniya a healing herb⁴. The whole *M. pudica* mainly grows on the hillside, jungle, glade, and roadside of Asia. Previous reports on *M. pudica* revealed the presence of bioactive compounds such as flavonoids and phenolics⁵. In addition, many bioactivities of *M. pudica* have also been studied such as antioxidant, antibacterial, hepatoprotective activities and so on. Hence, the present investigation is proposed to evaluate the healing activity of diabetic wound by the ethanolic leave extract of *M. pudica* in STZ induced diabetic excision wound in albino wistar rats. The % wound closure and histological appearance of wound is estimated to evaluate healing process.

Materials and Methods

Streptozotocin (STZ) was obtained from Sigma-Aldrich Chemical Co., St. Louis, MO, USA. All other reagents and chemicals used were of analytical grade procured from Hi-media Labs, Mumbai, India.

Plant material and extraction: The fresh leave of *Mimosa pudica* was harvested locally from southern parts of Odisha, India in the month of October-December. The plant was identified and authenticated at the department of Plant Research Centre (PARC) Chennai. The specimen was deposited in herbarium of PARC (Voucher Specimen No: PARC/2008/128). Plant material was carefully washed with tap water and left to dryness in dark at room temperature and finally stored in well closed cellophane bags. The shade-dried

and coarse powdered leave (2 kg) was subjected to defat with petroleum-ether (boiling point 40-60°C) using Soxhlet extraction apparatus (Quickfit, England). The defatted sample was air dried in order to remove solvent residue. Extract was prepared by extracting the defatted powder with ethanol solvent (80% v/v) for period of 48 h, which was then concentrated to a semisolid mass under reduced pressure (Buchi Rotavor R-200, Switzerland) for 20 min at 70°C (yield: 6.7% w/w). The extract was subjected to prepare 2.5% and 5% ointment of EMP in simple ointment base⁶.

Animals: Inbred adult male Charles-Foster albino rats (150-200 g), 2-3 months old, were obtained from M.K.C.G. Medical College, Berhampur, Orissa and were used in the study. The animals were grouped and housed in propylene cages lined with husk under standard condition (24 ±2°C temperature, 45-55% relative humidity and 12 h light: 12 h dark cycle). Animals were allowed to freely feed their standard pellet diet (Lipton India, Ltd., Mumbai) and water ad libitum. The animals were deprived with their food for 16-18 h before the experimental work starts but water is allowed ad libitum. All the experimental procedures utilized were performed in accordance with the approval of the Institutional Animal Ethics Committee (1275/ac/09/CPCSEA) under strict compliance of Committee for the Purpose of Control and Supervision of Experiments on Animals (CPCSEA) guidelines for the experimental studies.

Oral toxicity studies:

An acute oral toxicity study was performed according to "Organization for Environmental Control Development" guidelines (OECD: Guidelines 420; Fixed Dose Method) for oral administration of EMP. Albino wistar male mice (N=6, 150-200 g), overnight fasted for 18 h were used for the study. The EMP at a dose of 2000 mg/kg was administered and the rats were continuously observed for first 3 h for any gross behavioral, neurological or autonomic toxic effects and for any lethality in the experimental animals. There is no toxic symptoms are found in the experimental animals, hence the low dose:

2.5% and 5% ointment was prepared with simple ointment base.

Streptozotocine-induced diabetic wound model

The Diabetes was induced by a single intraperitoneal injection of freshly prepared Streptozotocin (55 mg/kg bd. wt.) dissolved in citrate buffer (pH 4.00) to overnight fasted rats⁷. Blood glucose level was measured by using commercial kit (GOD/POD method)⁸ and diabetes was confirmed on 4th day of the Streptozotocine injection. The rats with fasting blood glucose level more than 250 mg/dl were considered to be diabetic and were selected for the studies.

Induction of excision wound

On the 4th day of diabetes confirmation the rats were subjected to excision wound model. The animals were anesthetized by ketamine⁹ (100mg/kg bd. Wt. i.p) to clean the hair on the back side of rat by the help of shaving kit. Immediately a wound of 500 mm² was made which is shown in the figure¹⁰.

Experimental design to study for wound healing effect on diabetic rats^{11, 12}

The whole experimental schedule was made for 18 days. The animals are grouped into five groups (each contain 6 animals) such as Group I (Normal control), Group II (Disease control) and Group III (standard) are treated with vehicle, soframycin (framycetin sulphate) 2% respectively whereas the animals of Group IV and Group V were treated topically with EMP 2.5% and EMP 5% ointment respectively for 18 days. On the end of the study the wound healed area in mm² and the % of wound closure was determined. The measurement of wound areas in this wound model were taken on 0, 6, 12 & 18 days. The wound margins were traced on a transparent paper using permanent marker pen and then measured on a mm² graph paper (Planimetric method)¹³. The reduction in the wound area was expressed as % of the original wound size.

$$\% \text{ of wound closure} = \frac{\text{Healed Area (mm}^2\text{)}}{\text{Original Wound Area (mm}^2\text{)} \times 100}$$

Statistical Analysis: The results are expressed as the mean \pm SEM for each group. The obtained data are analyzed by one way

ANOVA followed by Dunnett's post-hoc test in prism 5. Differences were considered to be statistically significant at *p<0.05, **p<0.01, ***p<0.001.

RESULTS: The table No: 1 represents the occurrence of diabetes in albino wistar rats throughout the 18 days of study period. Treatment with EMP 2.5% & EMP 5% have shown better closure of wound area i.e 47.25 \pm 8.81 & 24.24 \pm 3.06 respectively when compared to disease control (145.75 \pm 10.13) whereas it was found to be 8.45 \pm 8.34 for framycetin (Table No.2). The normal control group has shown complete wound healing at the end of the study. The % of wound closure was found to be more in EMP5% than EMP 2.5% is depicted on the following graph. The histological study on 18th day depicts better wound healing activity with felt scar except disease control.

DISCUSSION

Wound healing in diabetes is a complicated and integrated process. There are many phases of wound healing such as granulation, collagenation and scar formation. In the present study the EMP showed a promising wound healing activity in excision diabetic wound model in diabetic rats. The various mechanisms like free radical scavenging, metal chelation, anti-inflammatory, astringent as well as immune modulation bring about the wound healing effects of the EMP. The EMP has also shown better collagenation and scar formation may be due to presence of phytochemicals like flavonoids, which are might be responsible for the topical free radical scavenging activity. The phenolic contents like c-glycosyl flavonoid, kaempferol and quercetin of EMP might be responsible for free radical scavenging as well as collagen enhancing action^{14,15}. The flavonoid in EMP might be responsible for wound healing activity due to its following characters such as reeducation in lipid peroxidation, astringent and antimicrobial^{16,17}. Therefore it is concluded that the EMP have wound healing activity of in diabetes and it may be suggested for treating various types' wounds in human beings. Hence a further study can be put forward to isolate the purified constituents & sketch out the complete mechanism of wound healing activity in diabetes mellitus.

Table No. 1: The fasting blood glucose level of different treatment groups.

Groups	0 th Day	18 th Day
NC	78.56±3.41	79.23±4.11
DC	318±4.42	364±5.15
FRA	338±5.26	348±4.39
EMP 2.5%	309±4.6	352±3.86
EMP 5%	333±6.4	360±4.28

Table No. 2: The effect of different treatment groups on closure of wound area (mm²)

Group	0 th Day	6 th Day	12 th Day	18 th Day
NC	497.25±3.07	241.15±8.42	113±7.43	0
DC	490.75±1.80	412.25±10.68	218.25±12.34	145.75±10.13
FRA	499.5±2.4	173.5±8.13**	23.5±8.77***	8.45±8.34***
EMP 2.5%	500.25±1.38	273.05±11.32**	95.06±11.42***	47.25±8.81***
EMP 5%	501.75±1.93	182.75±7.63**	70.75±7.55***	24.24±3.06***

Graph No. 1: The effect of different treatment groups on % of wound closure.

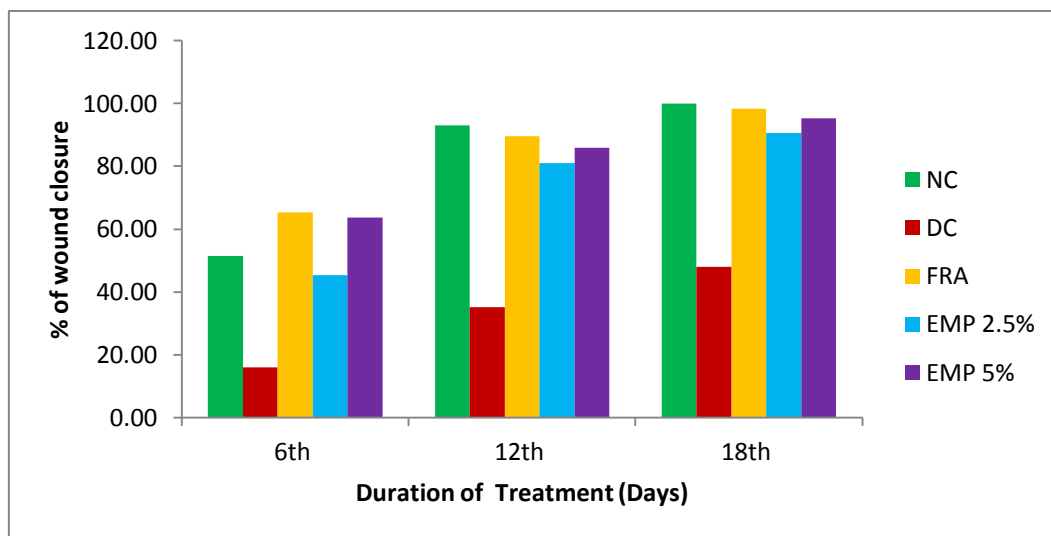
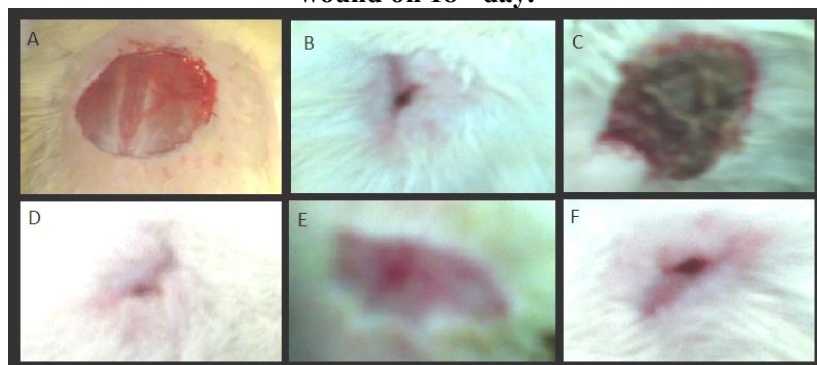


Figure No.1: The effect of different treatment groups on physical appearance (histology) of wound on 18th day.



A- Wound on 0th day; B- NC wound on 18th day, C-DC wound on 18th day

D- FRA wound on 18th day; E-EMP 2.5% wound on 18th day; F- EMP 5% wound on 18th day

Acknowledgement

Author is very much thankful to Dr. Bandana Rath (MD), Asso. Professor M.K.C.G. Medical College, Berhampur, Odisha for providing all the facility & requirements to accomplishment of the study.

REFERENCES:

1. Carvalho PTC, Mazzer N, Reis FA, Belchior ACG, Silva IS. Analysis of the influence of low-power HeNe laser on the healing of skin wounds in diabetic and non-diabetic rats. *Acta Cir Bras*, 2006; 21, 177-183.
2. Sherman, R. Maggot therapy takes us back to the future of wound care: New and improved maggot therapy for the 21st century. *J Diabetes Sci Technol*, 2009; 3, 336-344.
3. Streptozotocin-Induced Diabetic Rats. *J Med Food*, 2007;10, 323-329.
4. Modolin M, Bevilacqua RG, Ruy G. Cicatrizacao das feridas. Sintese das aquisicoes recentes. *Rev Bras Clin Terap*.1985. 14, 208-213.
5. A.K. Nadkarni. *Indian Materia Medica*. 2000; 779-780.
6. Yuan K, Lu JL, Jia A, Zhu JX. Two new C-glycosyl flavones from *Mimosa pudica*. *Chin Chem Lett*, 2007;18: 1231-1234.
7. Remington. *The science and practice of pharmacy*. 2000; (1): 1034.
8. Pari L, Murugan P. (2007). Tetrahydrocurcumin Prevents Brain Lipid Peroxidation in Streptozotocin-Induced Diabetic Rats. *J Med Food*, 10, 323-329.
9. Trinder P 1969 Determination of glucose using glucose oxidase with an alternative oxygen acceptor. *Ann Clin Biochem*. 6. 24-27.
10. Humaira Lateef, Omorodola I *et al*. Topical pretreatment of diabetic rats with all Trans Retinoic acid improves healing of subsequently induced abrasion wounds. *Diabetes*. 2005; 54:855-861.
11. Morton JJP, Malone MH. Evaluation of vulnerary activity by an open wound procedure in rats. *Arch Int Pharmacodyn* 1972, 196:117-126.
12. Diwan PV, Tilloo LD, Kulkarni DR: Influence of *Tridax procumbens* on wound healing. *Ind J Med Res* 1982, 75:460-464.
13. Patil PA, Kulkarni DR: Antiproliferative agents on healing of dead space wounds in rats. *Ind J Med Res* 1984, 79:445-447.
14. Raghavan Govindarajan, Madhavan vijaya kumar, Chandana Venkateswara Rao *et. al*. Healing potential of *Anogeissus latifolia* for dermal wounds in rats. *Acta pharm*.2004; 54:331-338.
15. Cronje, et al., "Oligomeric Flavanoids. Novel Prorobinetinidins and the First A- type Proanthocyanidin with a 5-Deoxy A and a 3,4-cis C- ring from the maiden Investigation of commercial wattle Bark extract", *J. Chem. Soc. Perkin Trans*.1993;(1) :2467-2477.
16. Balakrishna N, Suresh D, Pandian GS, Ediwn E, Sheeja E. Antidiarrhoeal potential of *mimosa pudica* root extract. *Indian journal of Natural product*. 2006; 22(2):21-23.
17. Tewaris S.N and Nayak M. Activity of four plant leaf extract against three fungal pathogens for rice. *Tropical agriculture*. 1991; (68): 375-393.
18. Tsuchiya H , Sato M, Miyazaki T, Fujiwara S, Tanigaki S, Ohyama M *et al*. comparative study on the antibacterial activity of phytochemical flavonones against methicillin resistant staphylococcus aureus, *J Ethnopharmacol*. 1996; 50: 27-34.